

What we do with your generous donations

From January 2011 – June 2011

Total Cost to BAAC: \$8,473.66

Total # of Animals: 27

4/5/2011 - \$250 Sydney – Dutch Ford Animal Hospital, South Carolina

Sydney is an adorable 9 month old pit mix that only weighed 19 lbs. She was almost starved to death, with no food or water, an upper respiratory infection and was found in deplorable conditions locked in a room. She has since recovered and has been adopted!! Below are her remarkable before and after pictures.



4/5/2011 - \$300 Braveheart – UW Veterinary Care, Wisconsin

Braveheart was found in a public dumpster with severe demodectic mange, sores all over his body, terribly emaciated and was infested with parasites. It is also believed that some of his sores were from being confined to such a small cage. Braveheart is still recovering from the life of severe neglect he has endured.




4/8/2011 - \$200 – Daisy – Titan Vet Services, Warwick, RI

Daisy is a 13 year old Shep/Lab mix who was looking for a new home after the only one she has known since she was a puppy decided they couldn't care for her anymore. It was discovered that she had not seen a vet since she was a puppy and was never spayed. At 13 years old, we don't recommend spaying, but we did get her tested for quite a few things and updated on all her vaccinations. She was also treated for a heart condition and upper respiratory.



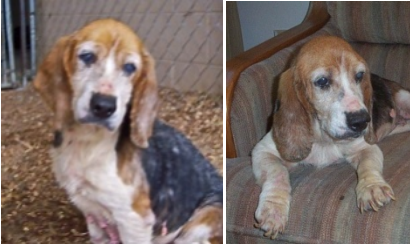4/12/2011 – Magoo – \$225.05 – Pieper Olson Veterinary Hospital, Middletown, CT

Magoo was an abandoned pit bull almost completely blind, heartworm positive, Lyme Disease positive, infested with whipworm and giardia. He was a mess due to a life of neglect. He has since been treated and is in foster care waiting on his forever home. Please contact Middletown Animal Control if interested.



4/15/2011 – Vanna – \$250.00 - Dutch Fork Animal Hospital, South Carolina

VANNA is an 8-10 year old beautiful BEAGLE that was abandoned down a dirt road in Georgia. Unable to see more than shadows, she has cataracts in both eyes and she has dry eye that has caused her to have a layer of green film that covers both eyes. Most of her teeth are missing and she has layers of skin that are just hanging off her. Her skin is red and raw over half her body from yeast, bacterial infections and Demodex.



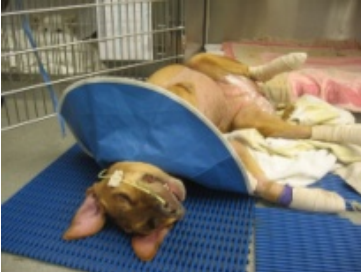4/21/2011 - \$300 – Penelope – Shoreline Veterinary Referral & Emergency, Shelton, CT

Penelope, who is a tiny Persian kitten with a smooshed face was the victim of a bad breeder. The details were fuzzy, but she sustained an injury to her right eye along with a lot of fluid in her lungs. Her right eye had to be removed and the fluid was drained from her lungs. Her fate was unknown, with only a 30% chance of survival, but she is a survivor and has persevered. Below are her before and after pictures:



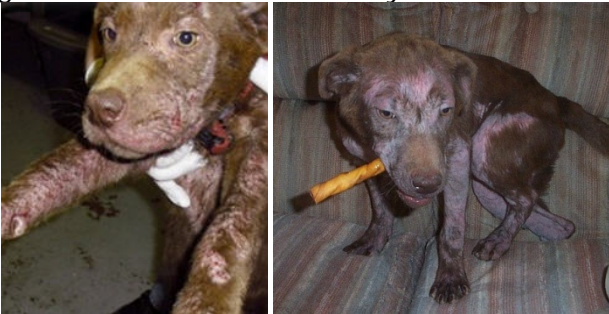4/21/2011 - \$300 – Abbey Bubbles – Animal Surgical & Emergency Center, Los Angeles, CA

Abbey had been left in an abandoned home. She was taken to a local shelter where she was sick and left with no treatment for the mandatory 10 days which made her condition worse. She was found laying in her run covered in urine, feces and blood. There were sores on her legs that went nearly to the bone. Abbey's muscles are so atrophied that she couldn't stand for any sustained period. A rescue took her in and after seeing her will for life, got her the medical help she needed.



4/28/2011 - \$300 – Twix – Dutch Fork Animal Hospital, South Carolina

Twix was a 12 week old chocolate lab mix when picked up as a stray. She was severely emaciated and covered with terrible infected sores. It was determined that she has demodectic mange and secondary skin infections from lack of treatment. She is slowly getting over the demodex, but still has some way to go. She was noted to be very smart and loving by her foster.



4/28/2011 – \$300 - Harley, Chelsea's Kitty – Port Cities Animal Hospital, Manitowoc, WI

After receiving a heart wrenching letter from a twelve year old little girl out in Wisconsin who was desperately trying everything and anything she could to save her beloved kitty, we unanimously agreed to help continue treatments and tests to try and save her life. Unfortunately, the kitty was suffering too much and to continue testing was no longer an option, therefore she was humanely euthanized. RIP Harley.



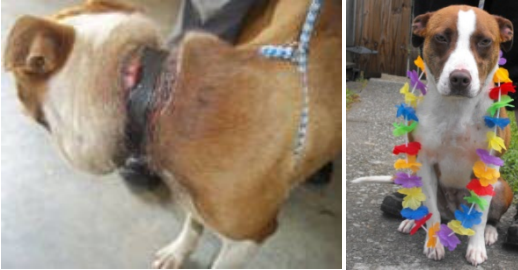4/29/2011 - \$300 – Moggie and Mollie – North Greenville Animal Hospital, South Carolina

Moggie and Mollie were 8 week old pitbull pups that were picked up as strays . They were both severely infected by a horrifying case of demodectic mange. The infection was so bad that their immune systems could not fight off anything. If the infection in their eyes went any longer they would not be able to see. They will be receiving treatment for several months.



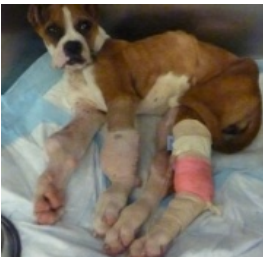4/29/2011 – \$300 - Pebbles and Elliot – Animal Medical Center of Boone, North Carolina

Pebbles was a 7 month old pit bull mix brought into animal control as a stray. She had a severely embedded collar that needed to be surgically removed. While at the shelter, she was rescued along with another pit with an embedded collar named Elliot, so we distributed our contribution towards the vet bill amongst both of them. As you can see by the pictures below, Pebbles has made a remarkable recovery and is currently awaiting adoption at Watauga Humane Society, Boone, NC.



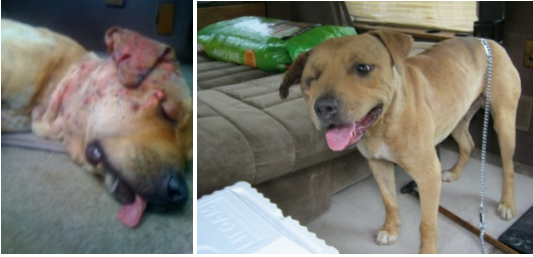5/3/2011 - \$250 – Pearl – South Carolina Veterinary Specialists

Pearl, was just a 12 week old puppy when found in the yard of an abandoned home in Los Angeles, CA and taken to a shelter. This adorable little puppy has seen a life of neglect in her short time, completely emaciated with a Bacterial Pneumonia and Developmental Orthopedic Disease. She was facing euthanasia until a kind hearted soul sought to rescue her. She has recovered from the pneumonia and will now face several surgeries and a lot of rehabilitation to help correct the DOD. She has since been moved to a rehabilitation center to properly care for her needs.



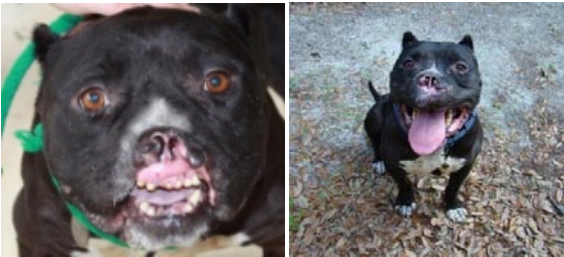
5/4/2011 – \$300 – Patches – Northgate Animal Hospital, Memphis, TN

Patches was rescued off the streets in the midst of a dogfight, pitted against two dogs. He had hundreds of scars from previous fights and thought to be fought daily by the neighborhood kids. From the fight he was rescued from, he incurred serious injuries to his head, jaw and neck area, on top of being heartworm positive. He has a long road to recovery ahead of him, but at least he is now safe, loved and knows compassion.



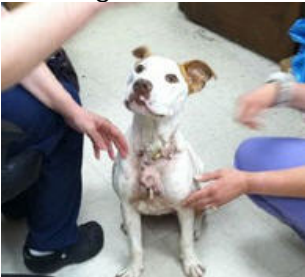5/9/2011 - \$250.00 – Tyson - South Carolina Veterinary Specialists

Tyson, a 6 year old Staffordshire Terrier/Pitbull Mix who was picked up as a stray in LA, CA. He appears to have been used as a bait dog based on sweet personality, old scars and the large chunk that had been torn off his upper lip and part of his nose. His injuries go inside his sinus cavity which is why he has a terrible sinus infection. Sweet Tyson had a terrible upper respiratory infection that went into his lungs. Once he recovered from Bacterial Pneumonia, he received reconstructive surgery to repair his upper lip and is now waiting for his perfect home at Noah's Arks Rescue, SC. Below are his incredible before and after shots:



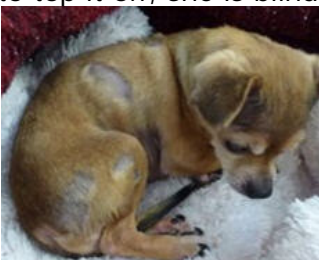5/31/2011 - \$300.00 – Princess – North Haven Animal Hospital, CT

Princess was a 9 month old pup who was brutally stabbed by her owner 29 times because as he told the police "Everyone is giving me a hard time about the dog". Princess miraculously survived the horrifying stabbing with her sweet disposition intact and is currently recovering.



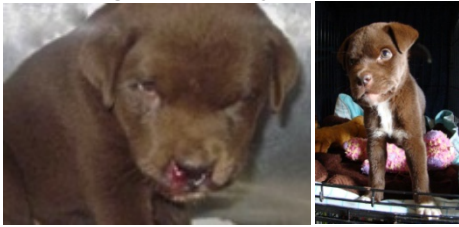6/2/2011 - \$250.00 – Judy – Dutch Ford Animal Hospital, South Carolina

Judy, an 8-10 year old female Chihuahua that was found on the side of a road in a box was covered with fleas and very dirty. Upon closer examination, it was discovered that her nails were so long they curled into the pads of her feet disabling her, her ears were so terribly infected that she had lost all hearing, her little body was covered with scabs and bald patches which is believed to be from demodectic mange and to top it off, she is blind. She is receiving lots of care to get her healthy again to find her a forever home.



6/6/2011 - \$300.00 – Stella – Coastal Vet – Boston, South Carolina

Stella at only six weeks old, was picked up as a stray. When found, she had blood running out of her nose unveiling that her jaw was broken in two places that go all the way into her sinus cavity. She will have to have several small surgeries to adjust the wires to allow her jaw to grow normally but other than that she is healing beautifully in foster care.



6/6/2011 - \$857.71 – Albi (aka Frankencat) – Ridgehill Animal Hospital, North Haven, CT

Albi was picked up as a stray cat from a good friend of B.A.A.C. who does feral rescue. He had a grossly infected wound on the left side of his head and neck and was on the skinny size. Being that he was a large cat and our friend had seen him in the past in much better condition, it was determined that he was once someone's pet who was then abandoned to fend for himself, which he did not fare well at all. He had to undergo surgery to remove the infected dead tissue and suture the wound, which there wasn't enough skin left to close the wound fully after all the dead tissue had been removed. While in surgery, we had him neutered. He has since been fully vaccinated as well and adopted into a perfect home where he will be an indoor cat for the rest of his life!



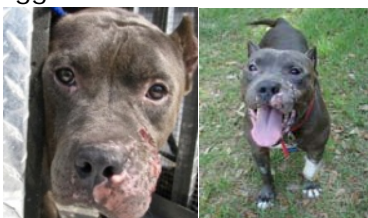6/10/2011 - \$414.20 – Dinah – Ridgehill Animal Hospital, North Haven, CT

Dinah was approximately 10 weeks old when found as a stray near a dog training facility in Hamden by one of our members. We had her taken to our vet who discovered that she was severely emaciated, had an upper respiratory infection, bacterial infection in both eyes with an ulcer in her right eye. She has since been completely treated, vaccinated and adopted into a forever home to be an indoor kitty for the rest of her life!



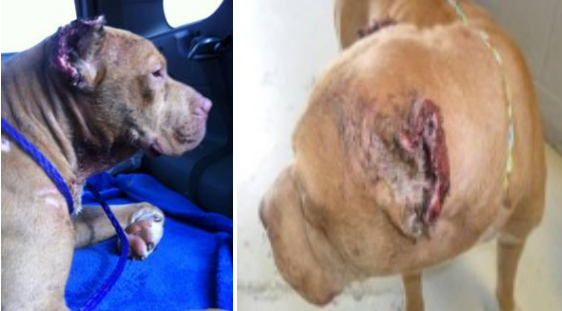6/10/2011 – 300.00 – Costello – Costal Vet, Bluffton, South Carolina

Costello, a 3-4 year old pit bull/Staffordshire terrier mix was found wandering down a road with his head hanging low and most of the left side of his face almost torn off and a large chunk taken out of his leg. It appears he was used as Bait Dog to train others to fight, mostly due to his extremely sweet disposition. He has since had reconstructive surgery on his face and leg and is healing beautifully. We are also glad to report that regardless of what humans and other dogs have done to him in his past, he shows no signs of aggression towards either! That's the power of a true pit bull's heart folks!!



6/13/2011 - \$300.00 – Anikan – Marek Vet Clinic, Bellville, TX

Anikan was in a ditch by a kind woman who just happened to hear his screams and cries for help from a distance. She kept trying to locate where the moans were coming from, and found what can only be imagined to be a horrifying scene. There in that ditch was Anikan. He was covered in blood, emaciated and whaling in misery. He was fighting for someone to find him, someone to rescue him and stop the pain. He had his ears butchered off, his testicles were either butchered off or severely mutilated, appeared to have been stabbed in the neck and was fighting infection all over. All signs of him being used as a bait dog or lost in an organized fight. He is still being treated as far as we know.

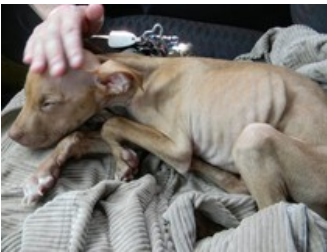

6/21/2011 - \$300.00 – Nirvana and Karma – Delaware County SPCA, Media, PA

Nirvana and Karma are 4-week-old kittens who were run over purposely by a psychopath in a truck who had planned to eat them for dinner. Both kittens were near death and covered in blood when roommates intervened and called in the authorities. They were both rushed to a vet clinic. Karma, who appeared to be the more seriously injured of the two, had to be placed into an incubator until she could breathe on her own. Her lower lip appeared to have been torn and there is blood on her mouth. They are continuing to be cared for.

6/22/2011 - \$250 – Cindy – Animal Kind, Brooklyn, NY

Cindy, a Pit bull puppy, was discovered in a rough area of Far Rockaway, NY. Her frail body had been left outside of a bodega, starved and discarded like trash. After being found, she was quickly rushed to a vet clinic where she is continuing to fight for her life.



Ongoing care for B.A.A.C. Rescue Lucky – still waiting for his forever home

Handsome Lucky is still with us waiting for his forever home and has costed us \$1,376.70 this quarter for boarding and annual veterinary visit.

